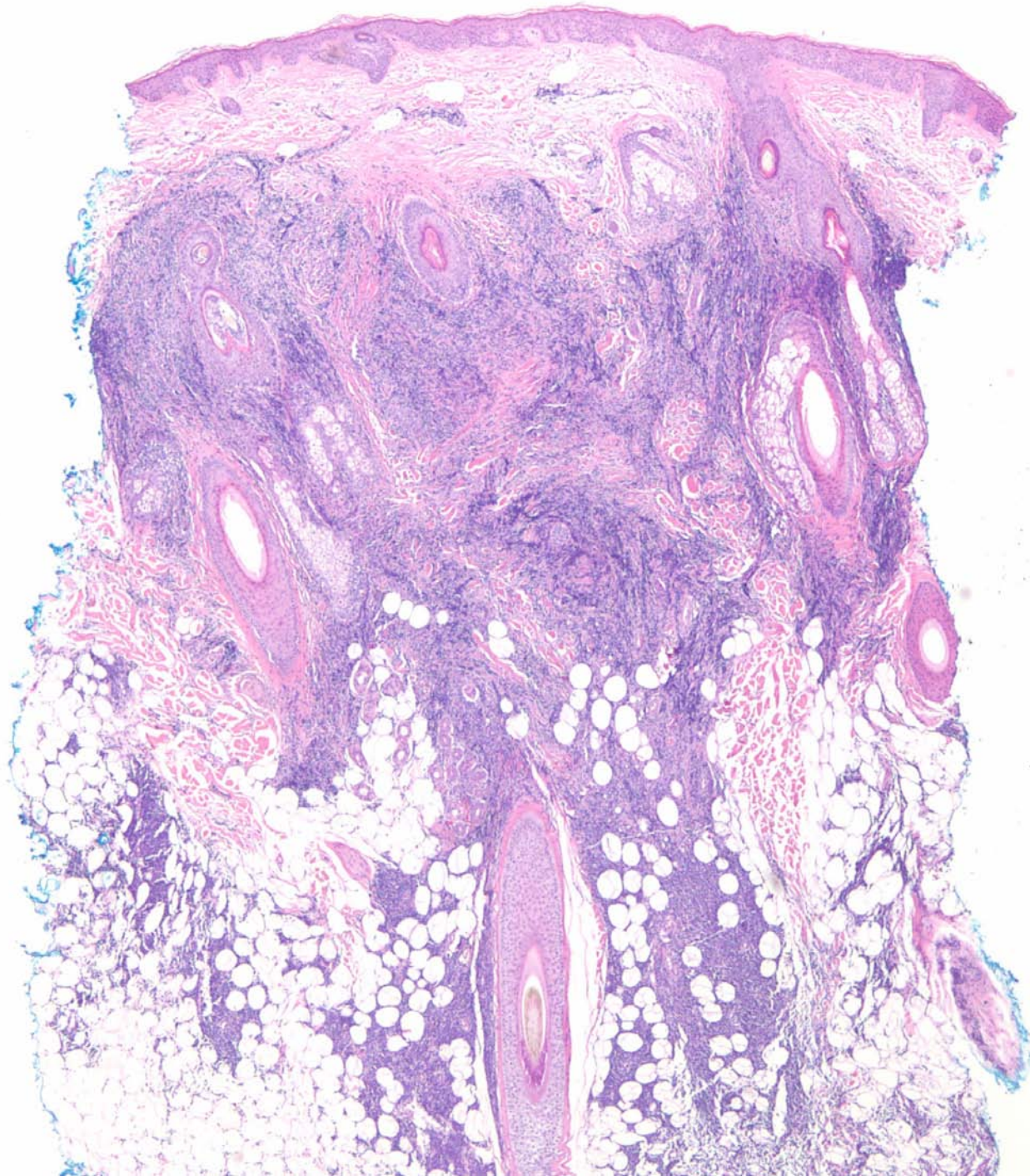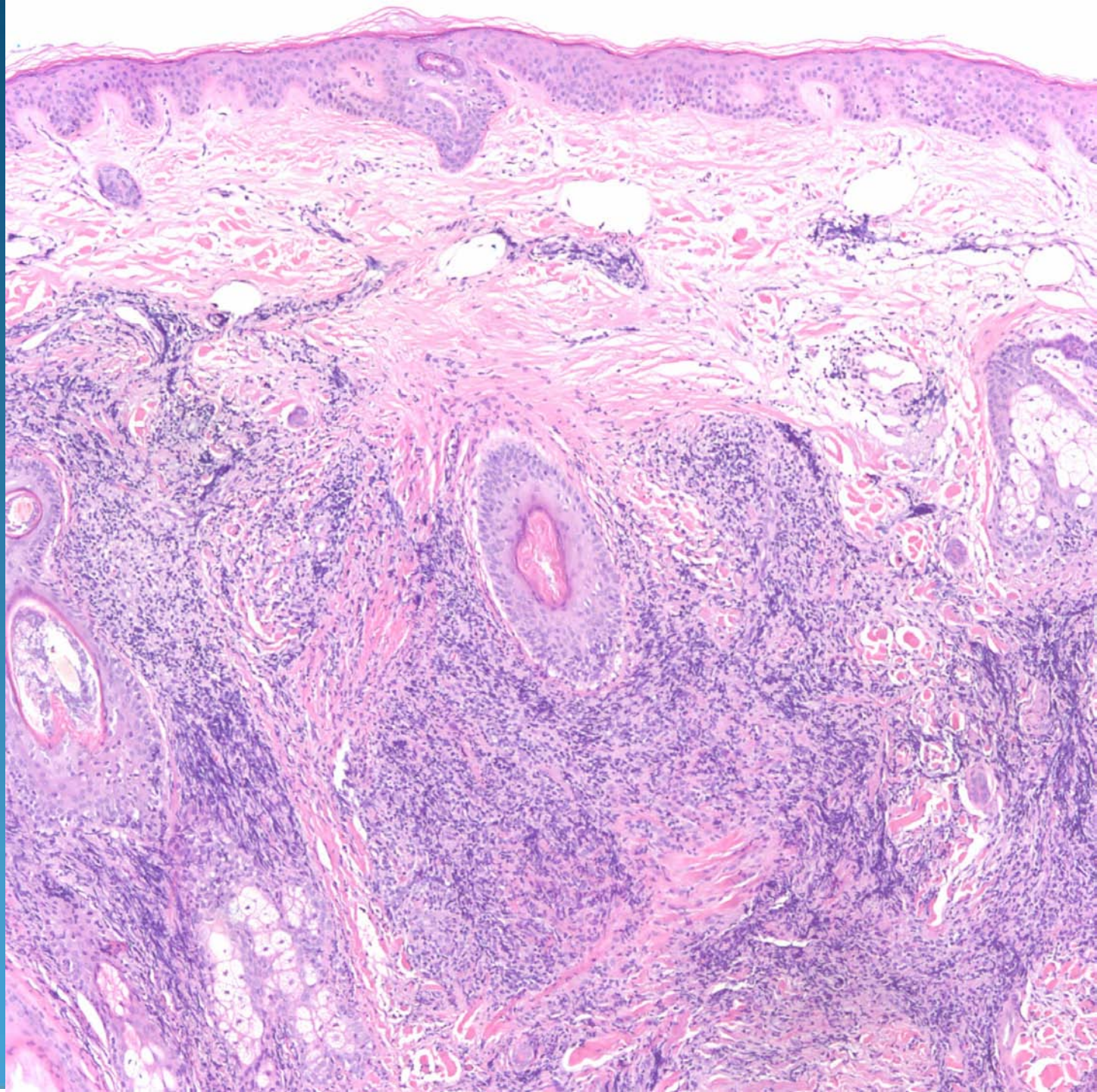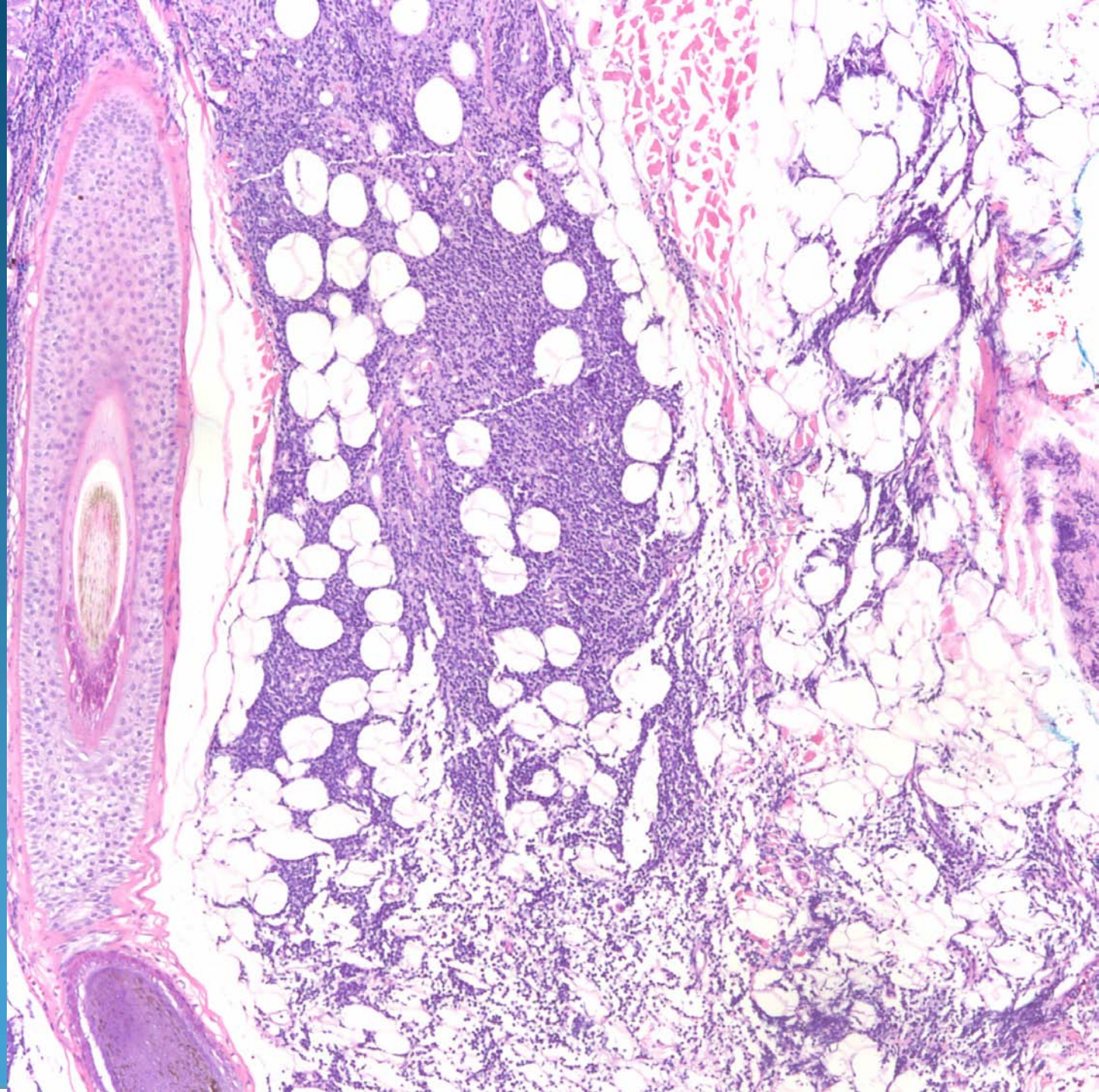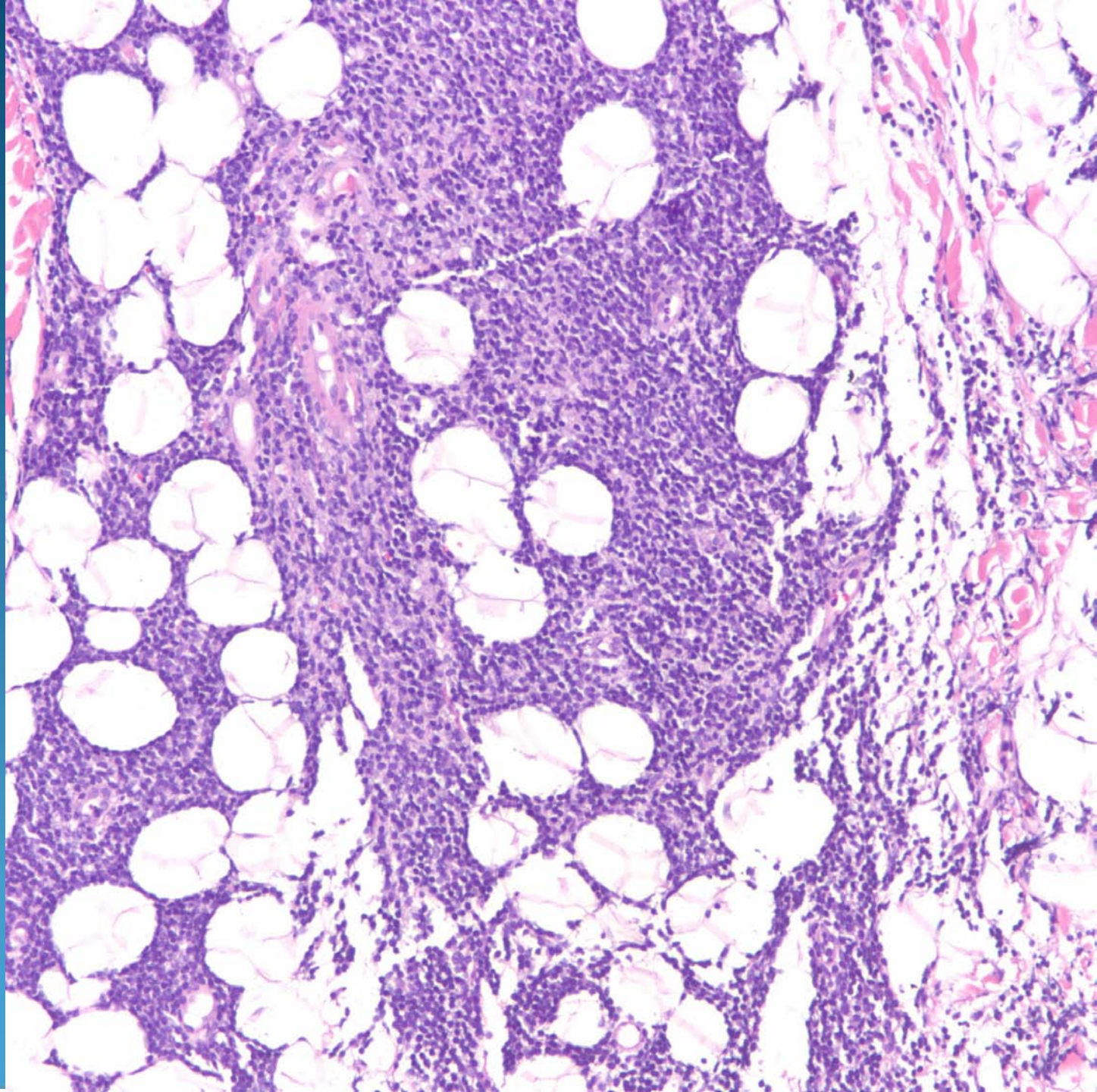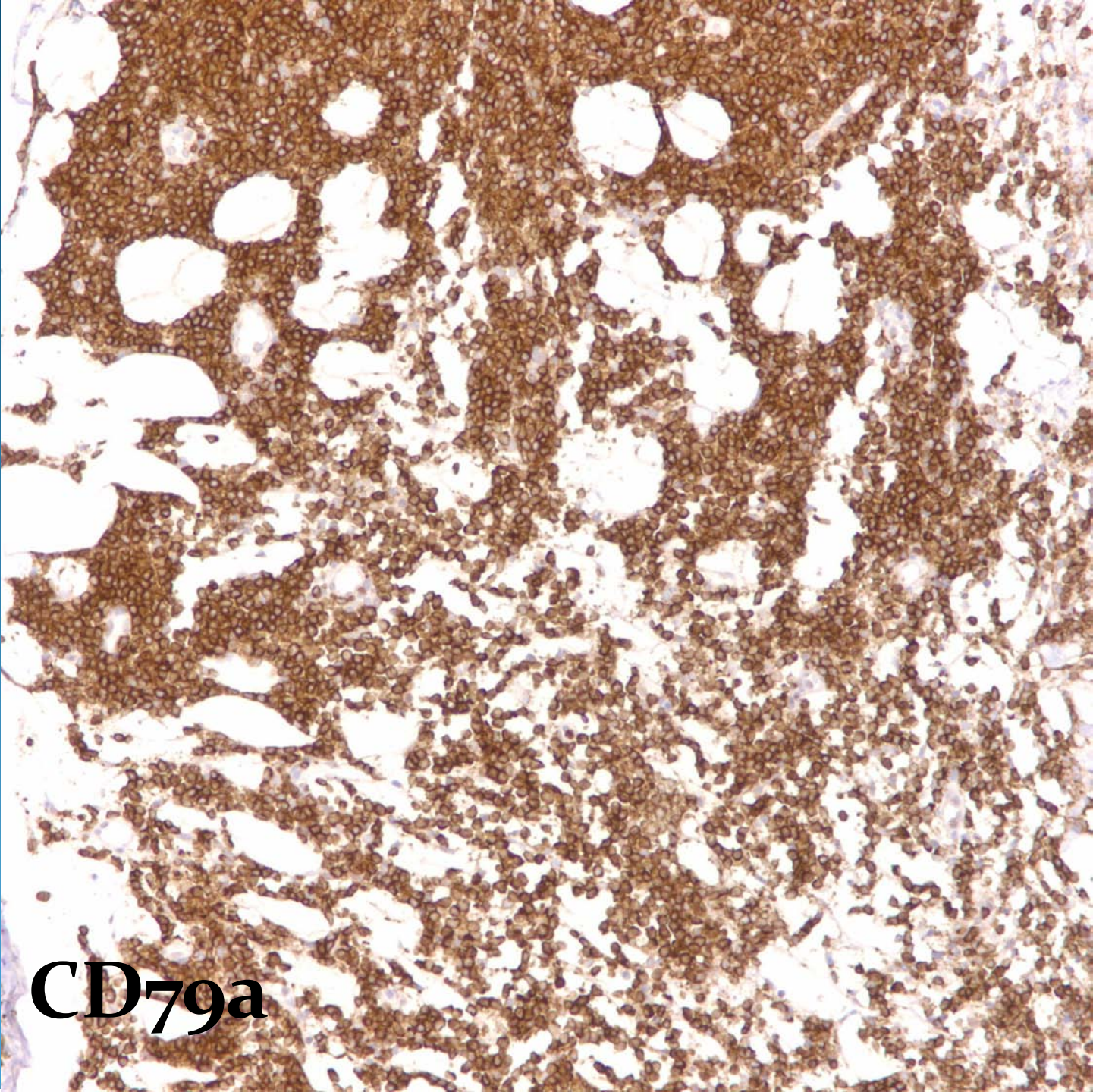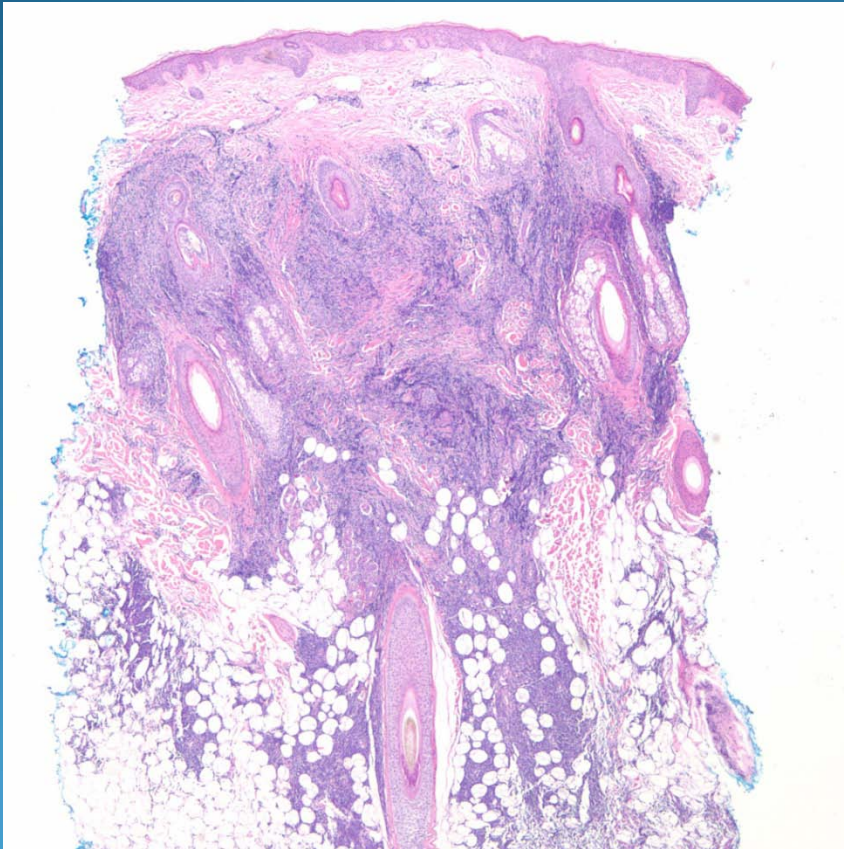


CD79a

Cutaneous B-Cell Lymphoma

Pearls



- Bottom heavy nodular and diffuse lymphocytic infiltrate, may extend into subcutaneous fat
- Grenz zone separating infiltrate from epidermis
- Confirm with IHC-CD20 and CD79+
- Subtype by morphology (size, cleaved contours, and IHC)